

Note: This is a sample EPoster. Your EPoster does not need to use the same format style. For example your title slide does not need to have the title of your EPoster in a box surrounded with a blue border.

# Orthodontic treatment of high-angle Class III malocclusion in a patient with impacted upper canine teeth

Names of Authors

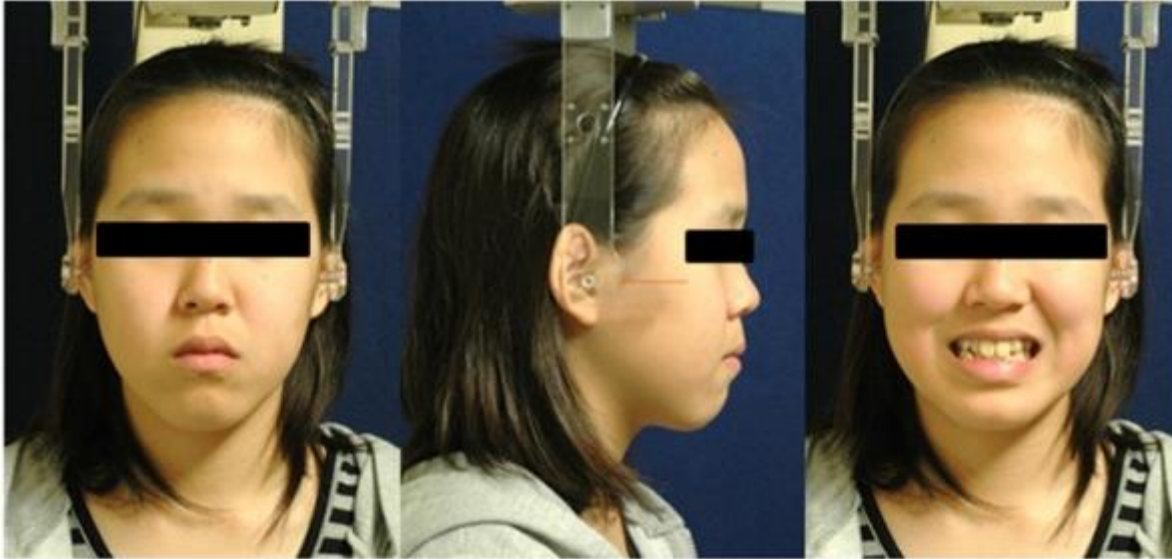# Introduction

The treatment strategy for Class 3 malocclusion is a trade-off between reducing the antero-posterior prominence of the chin and increasing the face height. In addition, dento-alveolar compensation by labial tipping of the upper incisors and/or lingual tipping of the lower incisors is usually involved. However, these changes are often undesirable for the facial profile. For this reason, camouflage treatment of Class 3 high-angle cases remains a major challenge for orthodontists. The treatment strategy for Class 3 malocclusion is a trade-off between reducing the antero-posterior prominence of the chin and increasing the face height. In addition, dento-alveolar compensation by labial tipping of the upper incisors and/or lingual tipping of the lower incisors is usually involved. However, these changes are often undesirable for the facial profile. For this reason, camouflage treatment of Class 3 high-angle cases remains a major challenge for orthodontists.

The present case report describes the application of camouflage treatment in a patient with Class 3 malocclusion with a high mandibular plane angle. Additionally, the bilateral maxillary canines were horizontally impacted with apparent follicle enlargement. The treatment involved the extraction of the upper impacted canines and lower premolars using TADs.

# Background information

The patient was a girl (age: 13 years and 6 months) with chief complaints of crowding and impaction of the upper canine teeth on both sides.



Convex soft tissue facial profile with retrograded chin

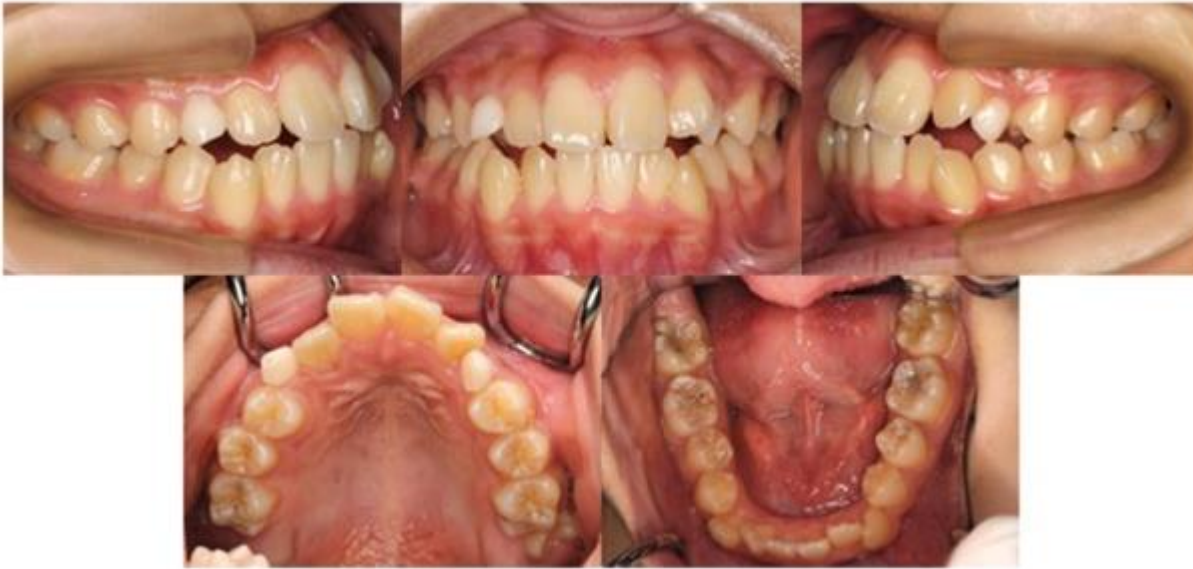Lower lip protrusion

Shallow labiomental fold

Lip incompetency

Long facial height

# Intraoral Findings



Crowding of the upper and lower anterior teeth

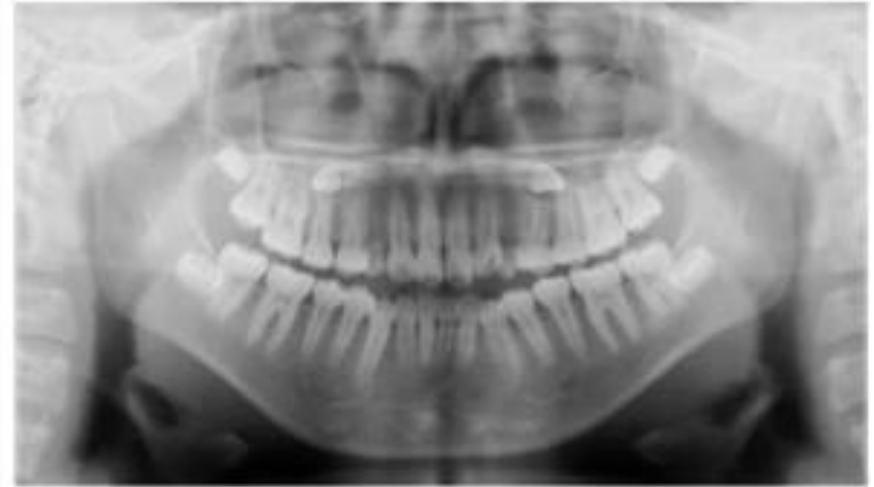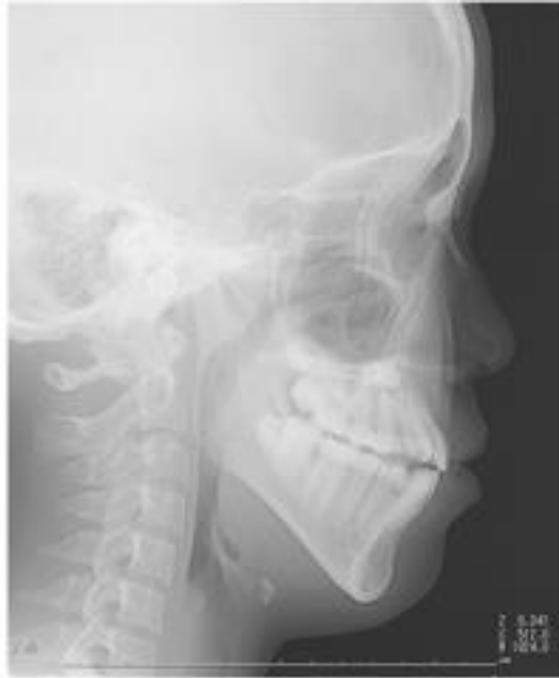Prolonged retention of the deciduous upper canine teeth on both sides

Angle Class III molar relationship with a tight overjet (1.8 mm)

Anterior open bite (overbite, -0.6 mm)

The curve of Spee was steep (3.0 mm)

# Radiographic Findings



Horizontally impacted canine teeth with circumferential follicular cysts on both sides

Skeletal Class 1 jaw base relationship ( $ANB = 1.5^\circ$ ) with a well-positioned and sized maxilla

Long mandibular body length ( $Go-Me = 74.1$  mm)

High mandibular plane angle ( $FMA = 41.8^\circ$ )

Lingually inclined lower incisors ( $L1-Mp = 80.6^\circ$ )

# Cephalometric measurements

Measurements	Pretreatment	Posttreatment	Retention	Normative Mean <sup>a</sup> (Japanese female adult)	
				Mean	SD
<b>Angular (deg.)</b>					
<b>SNA</b>	78	76.4	76.7	80.8	3.6
<b>SNB</b>	75.9	78	77.6	77.9	4.5
<b>ANB</b>	1.5	-1	-0.9	2.8	2.4
<b>FHMP</b>	41.8	37.4	37.6	30.5	2.1
<b>U1-SN</b>	108.7	103.9	103.4	105.9	8.8
<b>L1-MP</b>	80.6	73.1	73.6	93.4	6.8
<b>IIA</b>	120.2	136.2	135.8	123.6	10.6
<b>Linear (mm)</b>					
<b>S-N</b>	74.6	74.6	74.9	67.9	3.7
<b>N-Me</b>	137.5	138.1	138.7	125.8	5
<b>N/PP</b>	58.9	59.6	59.2	56	2.5
<b>Me-PP</b>	76.6	77.7	78.3	68.6	3.7
<b>Go-Me</b>	74.1	75.1	75.3	71.4	4.1
<b>Ar-Go</b>	46.2	50.9	50.5	47.3	3.3
<b>Ar-Me</b>	113	117.4	117.9	106.6	5.7
<b>Ptm-U6/PP</b>	20.5	25.3	26	19.4	3.3
<b>L1-MP</b>	48.6	45.7	45.9	44.2	2.7
<b>L6-MP</b>	34.9	33.6	33.7	32.9	2.5
<b>OJ</b>	1.8	4.4	4.1	3.1	1.1
<b>OB</b>	-0.6	2.3	1.8	3.3	1.9

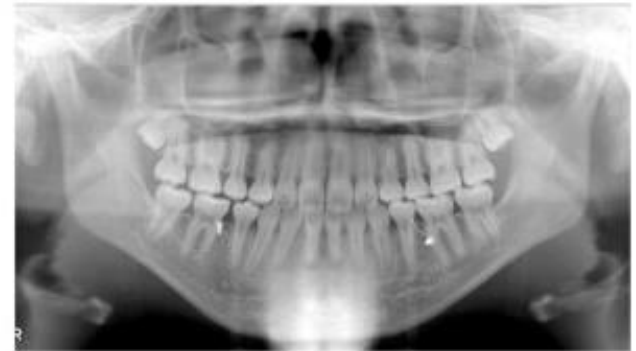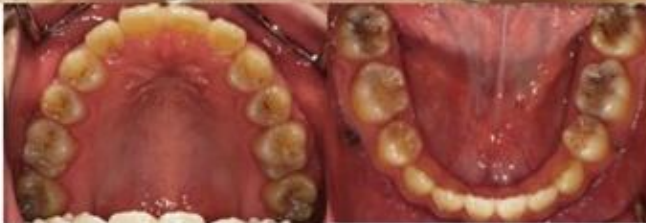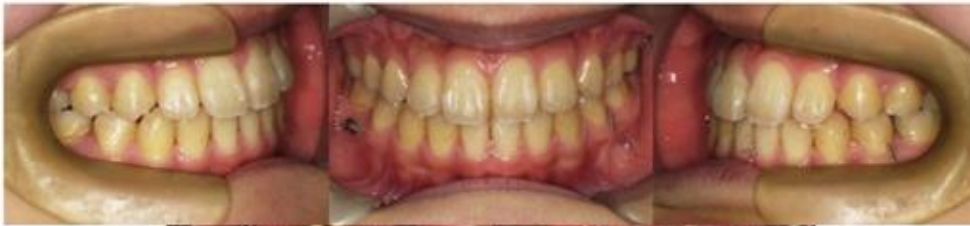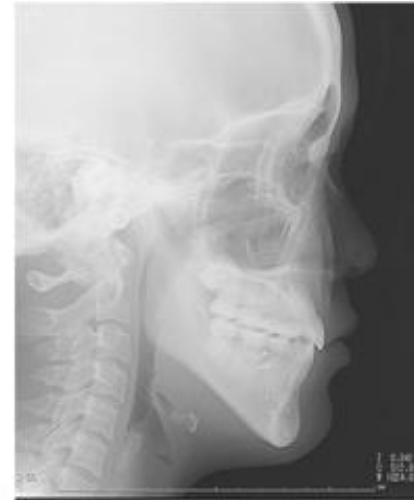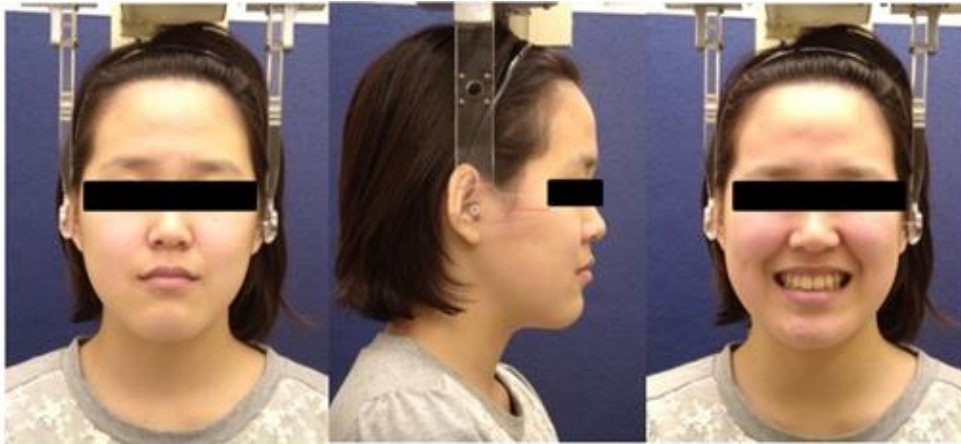## Problem List

1. Angle Class III molar relationship with a tight overjet
2. High mandibular plane angle
3. Long facial height
4. Anterior open bite
5. Crowding of the upper and lower anterior teeth
6. Horizontally impacted canine on both sides
7. Prolonged retention of the deciduous upper canine teeth on both sides
8. Lingually inclined lower incisors

## Treatment Plan

1. clockwise rotation of the mandible in order to improve the convex facial profile with a retrograded chin and long facial height
2. to achieve a good functional Class I molar relationship and establish ideal incisor relationships with retroclination of the mandibular incisors
3. the alignment of the upper and lower dental arches, including the impacted upper canine teeth.

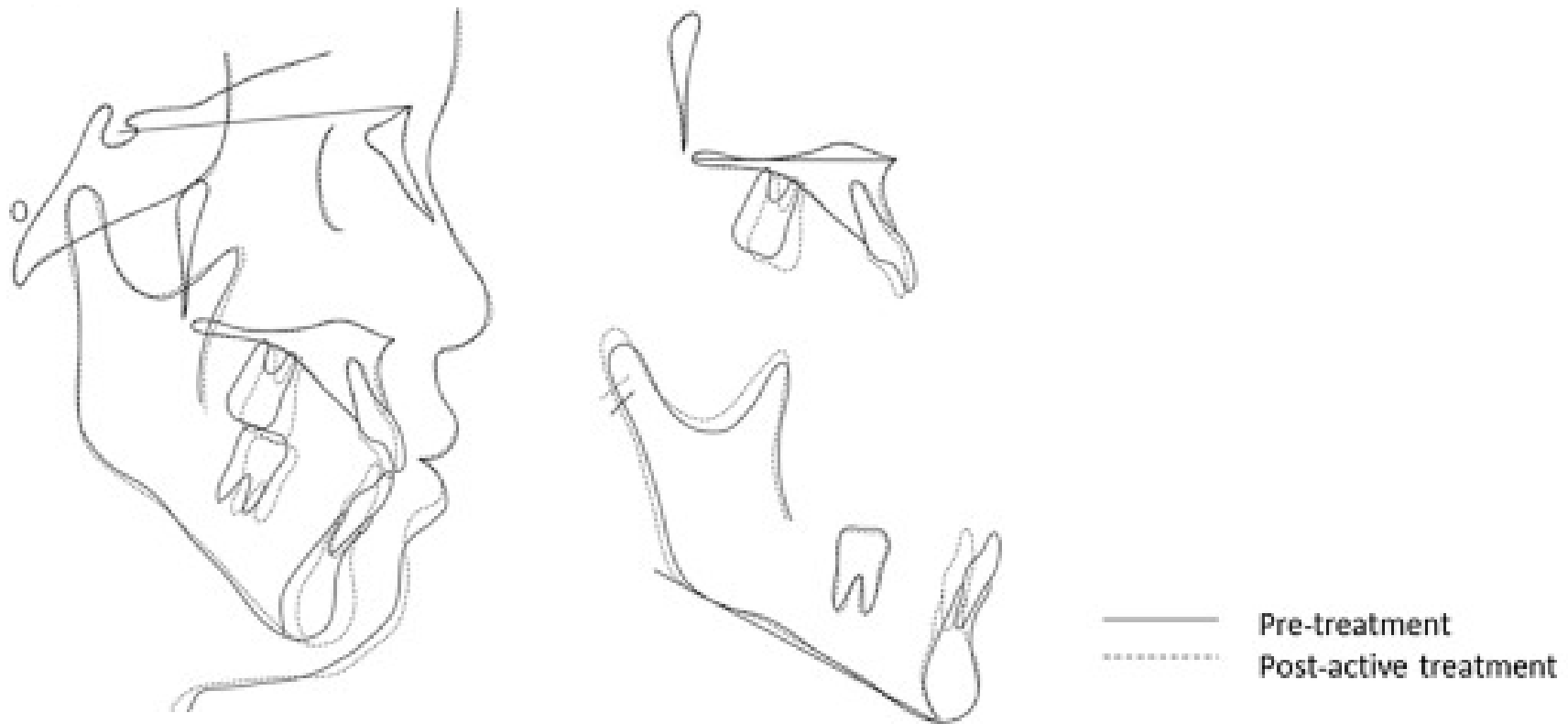
# Treatment Results



The convex type profile changed to a straight-type harmonious profile. The patient's Angle Class III molar relationship changed to a Class I relationship. The overjet was increased, and the lower lip protrusion was improved. The horizontally impacted upper canine teeth were extracted; thus, the upper first premolars were aligned with the original position of the canine teeth.

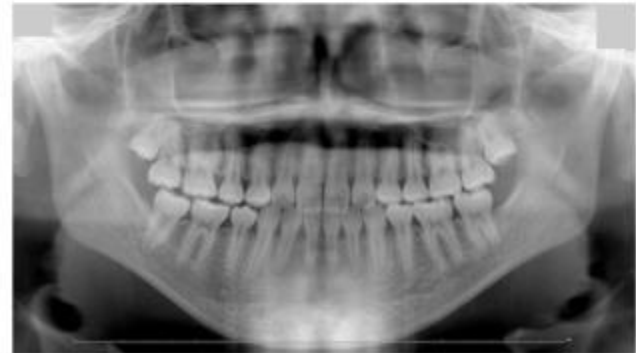
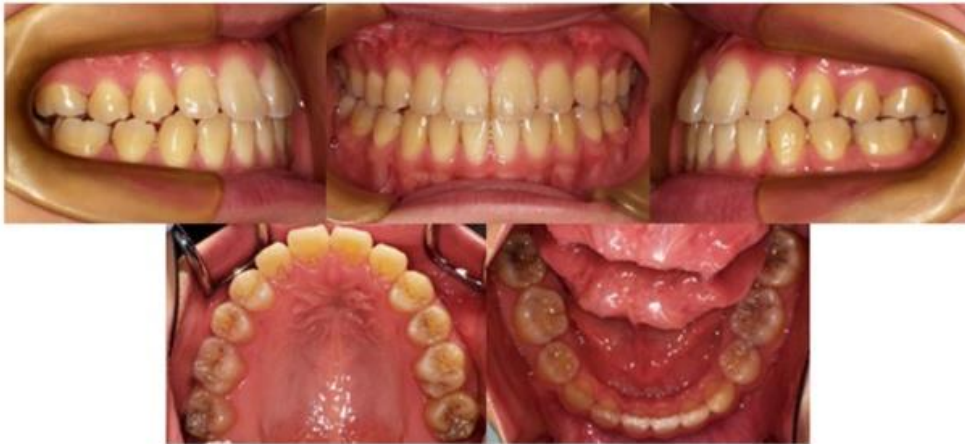
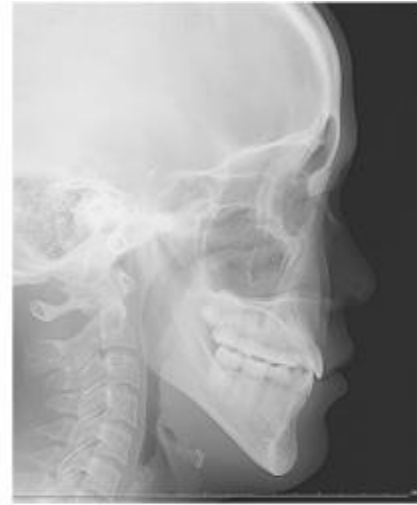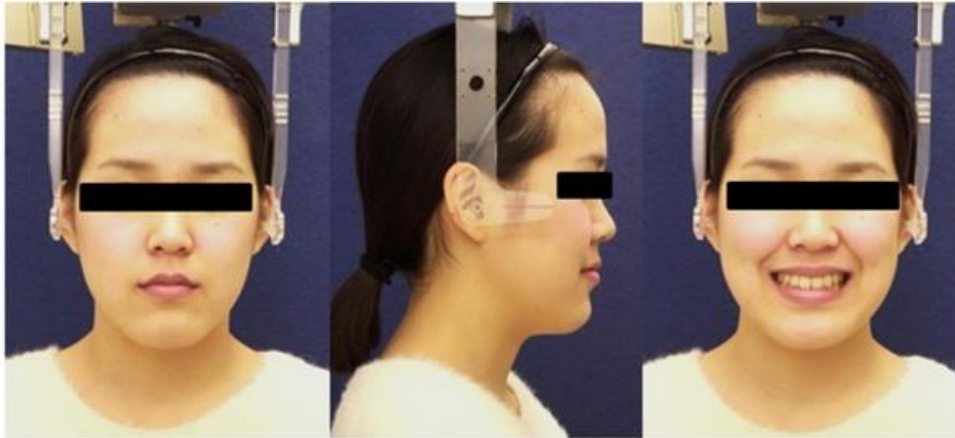# Superimposition of cephalometric tracings



The mandible showed autorotation with a small amount of growth. The lower molars were intruded and the FMA was decreased. The lower incisors were intruded and the overbite was increased. The length of Ar-Me increased. The Angle Class I relationship was achieved, as a result of the mesial movement of the upper molars while the anteroposterior position of the lower molars was maintained. The lower incisors were lingually inclined and the overjet was increased.

# Conclusions



In severe cases, such as cases involving high-angle Class III malocclusion in patients with a hyperdivergent facial profile, which may include contradictory or multiple problems and which have been conventionally hard-to-treat, TADs provide effective and efficient treatment. Further studies should be performed to expand the applications of TADs.